

# Impact of FDG-PET in patients with initially breast cancer based on unknown metastatic lesions detection and modified previous radiotherapy treatment planning: Preliminary study.

Pifarré P, Simo M, Escudero A, Plaza P, Marco V, Miralles E.

CRC Quirón, Barcelona, Spain.

## AIM:

Distant metastases at diagnosis are an important prognostic factor in patients with breast cancer and play a central role in treatment decisions planning. Also, on accurate detection of all nodal stations involved by tumour are essential for radiotherapy treatment planning. In this preliminary study, we investigated the utility of FDG-PET in this setting.

## MATERIAL AND METHODS:

21 women (mean age: 45 years old) with initially breast cancer were studied. Histological type included invasive lobular carcinoma (n=1), invasive ductal carcinoma (n=19) and medullary (n=1). All were unifocal breast carcinoma except one with multicentric neoplasm. Hormone receptor and HER2 were positive in 78% and 28% patients respectively. Seven patients had axillary nodal infiltration and four patients distant metastases previous PET scan acquisition. FDG PET studies were performed with a Biograph 6 slice from Siemens Manufactures. All lesions that changed treatment planning and with no morphologic correlation by CT were confirmed by histological analysis or RMI/Bone scan.

## RESULTS:

- All primary breast neoplasm was detected by PET/CT. Maximum SUV ranges were 2.57-12.85, with a mean value of 6. Lowest uptake corresponds to ductal carcinoma type.
- Ten patients showed nodal infiltration: axillary (n=4), internal mammary chain (n=1), axillary plus internal mammary chain (n=4) and axillary plus infraclavicular region (n=1).
- In 6 of these patients, radiotherapy treatment planning was modified.
- Suspected distant metastases were detected by PET/CT in 10 women: Bone (n=4), lung (n=1), liver (n=1), mediastinal (n=1), soft tissue (n=1) and multiple sites (n=1).
- 5 patients with morpho-metabolic discordance were confirmed by histological verification (n=4) or by RMI/Bone scan (n=1): Bone metastases were finally diagnosed in two patients and was rule out in other women with blastic bone lesions by CT.
- Two false positives for breast cancer metastases were founded: Invasive thymoma in patient with an hypermetabolic mass in the anterior mediastinum and a neurilemoma in upper abdomen.

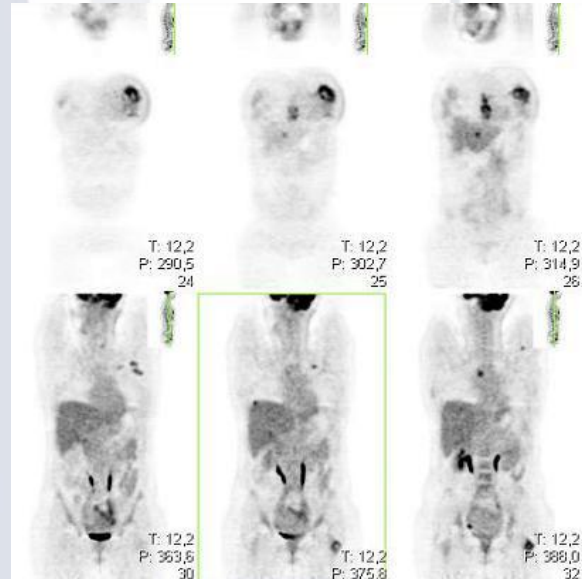


Fig 1. 42 years old woman with multiple metastases (bone, liver, mediastinum) from left invasive ductal breast carcinoma.

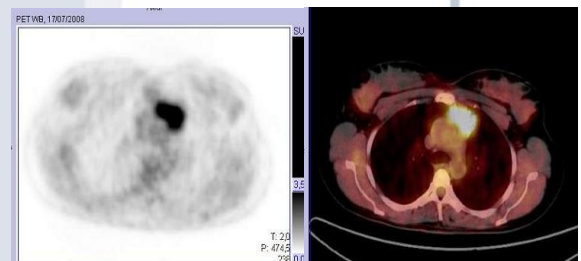
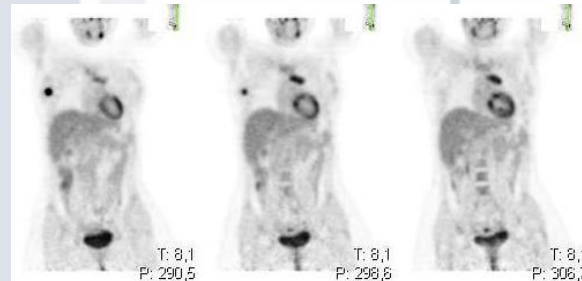


Fig 2. 38 years old woman with right breast cancer and an hypermetabolic mass in mediastinum. Finally biopsy reveals a malignant thymoma.

## CONCLUSION:

PET/CT can provide information on extra-axillary lymph node involvement and can detect occult distant metastases in a significant percentage of patients. Solitary distant lesions detected by PET had to be verified